

# How to improve surgery on the tendons of the hand and fingers.

M. MERLE\* - G. DAUTEL\*\* - C. DUMONTIER\*\*\*

* Michel MERLE :	Chef du Service de Chirurgie Plastique et Reconstructrice de l'Appareil Locomoteur au CHU de NANCY - Hôpital Jeanne d'Arc - 54201 TOUL Cedex. Co-directeur de l'Institut Européen de Biomatériaux et de Microchirurgie Université Henri Poincaré - NANCY I - CHU Brabois - 54500 VANDOEUVRE.
** Gilles DAUTEL :	Professeur de Chirurgie Infantile - Hôpital d'Enfants - CHU Brabois - 54500 VANDOEUVRE.
*** Christian DUMONTIER :	Institut de la Main - Clinique Jouvenet - 6 Square Jouvenet 75016 PARIS.

---

**S**urgery of the tendons of the hand and the fingers still seems difficult and haphazard. In fact, while no technical revolution has transformed by itself the functional prognosis of this surgery, it is especially by the accumulation of technical details and by better knowledge of the anatomy, the physiology, the cicatrisation and the biomechanics that the results have been clearly improved.

The major problem remains that of adhesions, which are intrinsic in all tendon surgery. The advent of a biodegradable gel will reinforce an entire therapeutic arsenal for preventing adhesions.

## 1 Anatomy of the tendon systems.

### A) The flexor tendons of the fingers.

These are so-called "extrinsic", because their muscle body is inserted in the forearm.

The international classification has determined 5 anatomical zones for the long fingers and 3 for the thumb (Fig. 1).

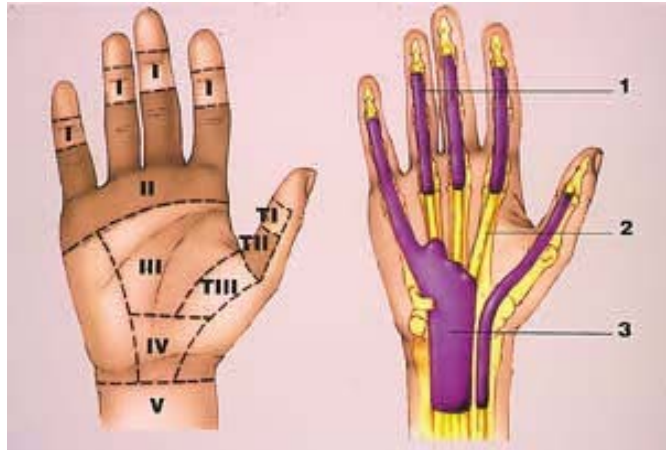


Fig. 1 : The International Federation Society of Surgeons of the Hand (I.F.S.S.H.) has determined 5 anatomical zones for the long fingers and 3 for the thumb  
Zone 2, so-called "no man's land" in English, corresponds to the digit channel, also known as the zone of Verdan and Michon.

Fig. 3 : Organisation des gaines synoviales des tendons fléchisseurs. Le long fléchisseur du pouce a sa propre gaine. L'index, le majeur et l'annulaire ont une gaine individualisée dans le canal digital. L'auriculaire a une gaine commune aux tendons fléchisseurs des doigts longs.

Zone 2, so-called "no man's land" in English, corresponds to the digit channel lying between the neck of the metacarpal and the middle part of the second phalanx. This osteo-fibrous, inextensible 'channel is formed by annular and crossing pulleys which apply the superficial and deep flexors against the skeleton and enable the complete unfolding of the digit chain (Fig. 2). If the pulleys are retained This function is total if pulleys A1, A2, A3 and A4 are preserved. The cruciform pulleys can serve as a starting channel for the repair of tendon. It is in the digit channel that the risks of tendon locking are the most common.

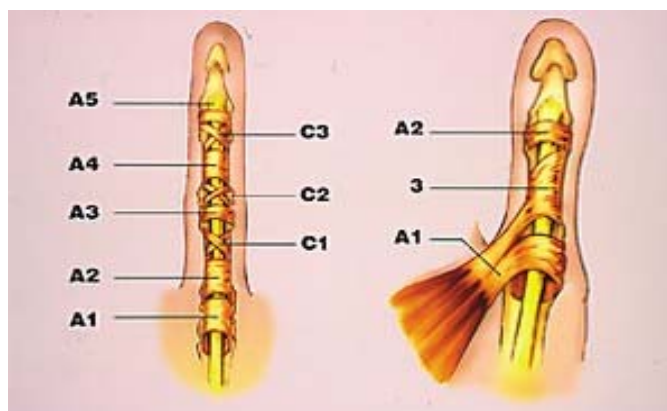


Fig. 2 : - Les poulies des doigts longs : le canal digital est formé de 5 poulies annulaires (A1 à A5) et de 3 poulies cruciformes (C1 à C3).  
- Les poulies du long fléchisseur du pouce : 2 poulies annulaires A1, A2 et 1 poulie oblique (3) constituent le canal digital.

The synovial sheaths assure the nutrition and the sliding of the tendons; thus, the surgical strategy is to preserve them and to close them up again after the tendon repair (Fig. 3) [9].

### B) The extensor apparatus.

- This is the meeting of the extrinsic extensor tendons and the intrinsic apparatus in the area of the metacarpal-phalangeal joint (Fig. 4).

The characteristics of the flexor apparatus of the fingers cannot be transposed to that of the extensor apparatus, since only the extensors situated beneath the dorsal annular ligament of the carpus are surrounded by a synovial sheath. The entire remainder of the extensor apparatus is extrasynovial and has a high capability of adhesion in the area of the metacarpal-phalangeal skeleton.

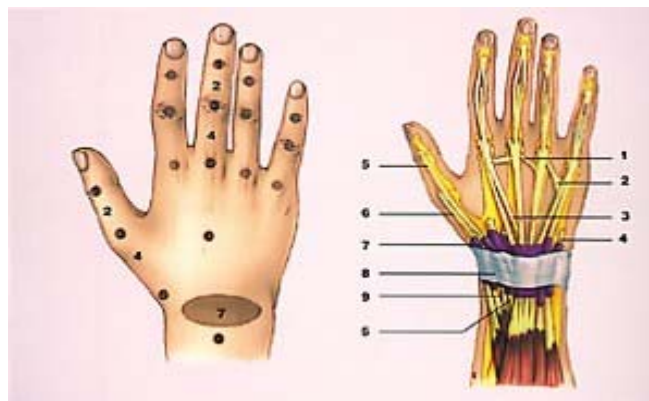


Fig. 4 : Anatomie de l'appareil extenseur extrinsèque.

- 1- Jonctions intertendineuses
- 2- Extenseur propre de l'auriculaire
- 3- Extenseur commun des doigts
- 4- Cubital postérieur
- 5- Long extenseur du pouce
- 6- Court extenseur du pouce
- 7- Gaine synoviale
- 8- Ligament annulaire dorsal du carpe
- 9- Premier radial

Fig. 5 : Les zones topographiques de l'appareil extenseur selon la classification de la Fédération Internationale des Sociétés de Chirurgie de la Main. Les numérotations impaires correspondent aux zones articulaires et les numérotations paires aux zones diaphysaires. 4 zones précédées de la lettre "T" sont dévolues au pouce.

-Verdan [2-3] has proposed a topographical classification of the extensor apparatus (Fig. 5). The odd zones 1-3-5-7 correspond to the wrist articulation zones 1PDAPP-MR. The even zones 2-4-6-8 correspond to the diaphyses. The articulation zones are exposed to trauma and injury to the extensor apparatus in this area creates a kind of Finger Mallet (zone 1) with a late consequence being a swan's neck deformity, a buttonhole deformity (zone 3), a luxation of the extensor in the intermetacarpal valley in event of rupture of the strap (zone 5). Zone 7 is

exposed to locking, given the tightness of the osteo-fibrous channel, even despite the presence of a synovial sheath.

## 2) Physiology of the cicatrisation.

- Numerous experimental works indicate that tendon cicatrization proceeds by two mechanisms, one extrinsic corresponding to fibroblastic invasion of the repaired zone, and the other intrinsic, due to the tendon's own capability of cicatrising.

- Based on the works of Peacock [18], Potenza [20], Lind say [8], Manske [1] have described the successive phases of tendon cicatrization:

1. Phase of migration of fibroblastic cells of peripheral origin toward the tendon injury, providing for production of collagen.
2. Phase of production of aggregating proteins and collagen fibers which glue the extremities of the tendon and the surrounding tissues. This appears from the 4th day on.
3. Phase of tendon cicatrization, remodelling and reorienting the collagen fibers axially, between the 3rd and the 8th week.

- This study of the physiology of the cicatrization shows that from the onset of phase 2 the patient should take advantage of all the procedures to counteract this tendency of gluing to the surrounding tissues by making use of all the techniques for protected mobilization and the inhibitors of adhesion or the inducers of sliding surfaces, such as ADCON-GEL, yet without influencing the mechanism of cicatrization and remodelling of the tendon callus. [16].

## 3) Technical procedures capable of improving cicatrization and tendon sliding.

### A) The flexor tendons of the fingers.

- **Surgical atraumatism or microtraumatism is essential** to minimizing the devascularization and the risk of adhesion of the tendon. Clamping forceps and tendon extractors blindly probing for the proximal extremity of the tendons in the digit channel are unacceptable. A simple and atraumatic means consists in using a flexible catheter, or a silicone rod, which is thrust against the proximal tendon. A counterincision makes it possible to secure it and extract it (Fig. 6). [15].

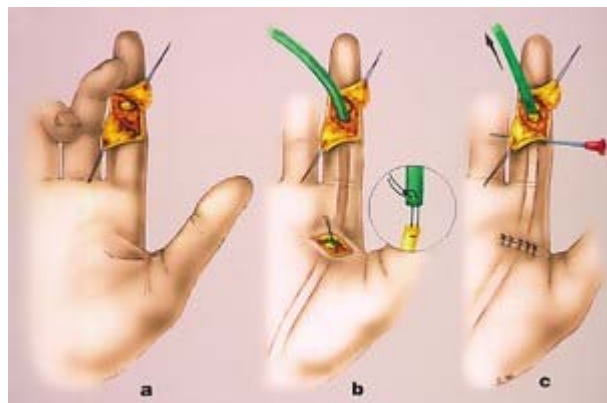


Fig. 6 : Méthode d'extraction atraumatique des tendons fléchisseurs.

- a) Une tige en Silastic est introduite par la plaie et vient buter contre le ou les tendons sectionnés.
- b) Une contre-incision permet de solidariser la tige de Silastic au tendon en utilisant le principe de la suture axiale selon Tsuge.
- c) Le tendon extrait est alors fixé au canal digital par une aiguille intradermique.

To preserve the pulleys A1, A2, A3 and A4, it is preferable to perform the extraction and the repair of the tendon by sacrificing a cruciform pulley. The tendon is fixed to an annular pulley by means of a hypodermic needle during the repair phase (Fig. 7).

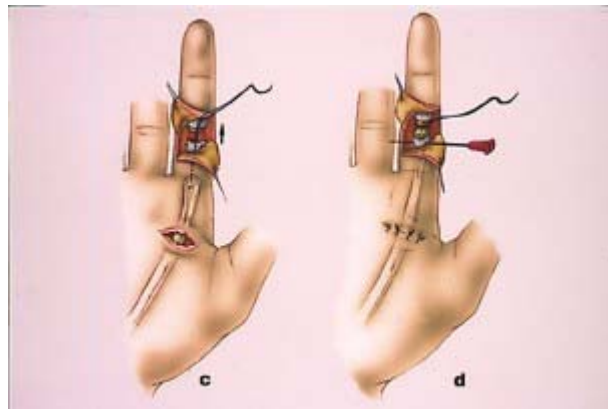


Fig. 7 : Alternative pour l'extraction des tendons fléchisseurs.

C'est la traction sur le fil de Tsuge qui extériorise les tendons fléchisseurs. Ils sont fixés provisoirement par une aiguille transfixiant la gaine fibreuse et les tendons. La suture proprement dite peut commencer.

- **The choice of the suturing technique** is important, as it may or may not allow an active mobilization. The number of suture threads increases the strength of the repair, but the more knots there are, the greater the risk of adhesion.

A suture implanted in the dorsal part of the tendon is stronger than a suture moved to the palmar side, but it is less ischemiant.

Our choice of suture for a protected mobilization of Kleinert or Duran type gives preference to an axial suture per Tsuge [22] (PIDS 3-0), supplemented by a peritendinous running suture made from Prolene.6-0 (Fig. 8).




Fig. 8 : Suture axiale selon TSUGE.  
Le fil résorbable de PDS est monté en boucle sur une aiguille. L'ancrage proximal s'effectue à 8-10 mm de la section tendineuse puis les fils cheminent dans le tiers antérieur. Ils ressortent de manière symétrique à la partie distale du tendon, un des fils est alors sectionné, le fil restant repasse une fois transversalement dans le péri-tendon avant d'être noué au fil précédemment coupé. Un surjet de 6/0 assure l'étanchéité du péri-tendon.

If the deep flexor tendon is large, two axial stitches per Tsuge are possible in parallel.

It is preferable to start the repair with a posterior peritendinous half running suture, then introduce the two axial Tsuge sutures, and finish up with an anterior half running suture.

- If one opts for an active protected mobilization, amplified by the effects of wrist tenodesis by the protocol of Cannon 0) and Gettle, one should reinforce the suture by making two box stitches per Tajima-Kessler [51, supplemented by a peritendinous running suture. The rupture strength, which is 1.4 kg with a Tsuge stitch made of PIDS, increases to over 3 kg with a Tajima-Kessler double stitch, as proposed by Strickland [21] (Fig. 9).

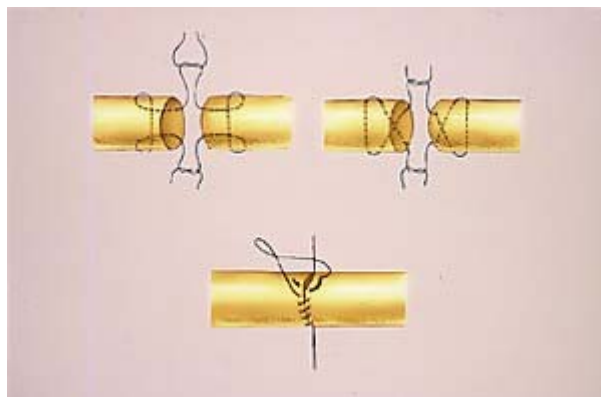


Fig. 9 : La suture en cadre selon Kessler-Tajima se noue dans l'interface tendineuse comme la suture en croix de Kleinert. Un court surjet épitendineux réalisé au fil 6/0 assure l'étanchéité de la suture.

- **The closure of the synovial sheath** [91, when such is possible, reestablishes the synovial pump (Weber) (Fig. 10) [24], which contributes to improving the tendon cicatrization and minimizing adhesions. Early mobilization of a suture activates the cicatrization and increases the strength while minimizing adhesions and increasing the excursion of the tendon, given the fact that the scar loses 25% of its mechanical qualities between day 8 and 21.

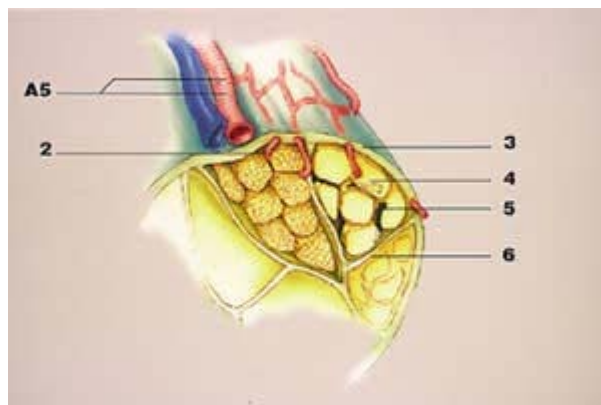


Fig. 10 : Mécanisme de nutrition du tendon par la pompe synoviale selon Weber. Le liquide synovial diffuse entre les fibres tendineuses pour alimenter les tendinocytes et s'évacue ensuite par le système vasculaire dorsal.

- 1- Système vasculaire dorsal
- 2- Système vasculaire interdentieux
- 3- Péritendon
- 4- Fibre tendineuse
- 5- Circulation du liquide synovial entre les fibres
- 6- Cloison fibreuse

- **The ideal moment of repair:** while isolated injury to the flexor tendons can be treated without damage during the first 48 hours of the accident, an attitude of strict urgency should be adopted when there are associated injuries. Sectioning of the two collateral digital arteries produces ischemia of the finger and tendons, whose vascular supply is known to be fragile.

Not to repair these vessels means a functional limitation due to scar fibrosis and gluing of the sliding spaces.

The collateral digital nerves should likewise receive a primary microsurgical repair, given the fact that the quality of reinnervation is directly dependent on the quality of the tissue bed and, thus, the revascularization of the finger.

It is just as essential as it is easy to make a local ribbon which will protect the major tissues repaired.

- **Postoperative care.** Education of the patient and his or her understanding is indisputably the key to the functional prognosis. His or her capacity to assimilate

the postoperative care will also govern the choice of the method of immobilization.

We no longer perform surgery on the flexor tendons in an outpatient setting. The patient is hospitalised several days in order to implement the reeducation protocol.

Our experience [13] [14] these past 20 years has been based on the technique of Kleinert [6] and Duran [41] (Fig. 11-12).

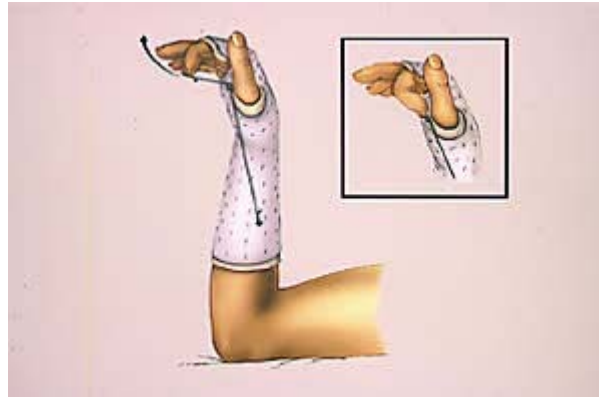


Fig. 11 : Principe de la mobilisation active protégée selon Kleinert. L'orthèse fixe le poignet en flexion à 30° et les articulations métacarpophalangiennes à 60°. Les articulations IPP et IPD sont libres. Au repos, l'élastique qui se réfléchit dans une poulie fixée en regard du pli palmaire distal, rappelle le doigt opéré en fléchissant l'IPP et l'IPD. Seule l'extension active contre résistance de l'élastique est autorisée, le rappel en flexion s'effectue passivement par l'élastique.

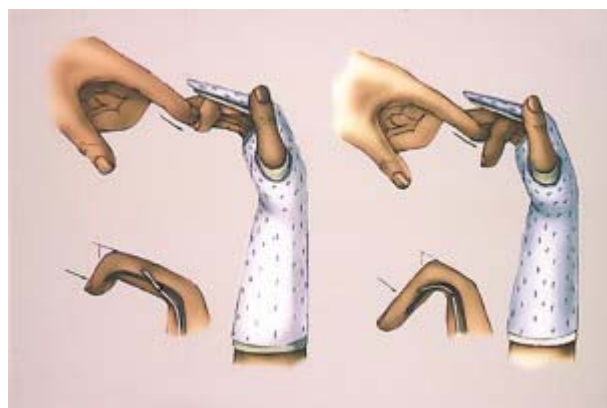


Fig. 12 et 12 Bis : Technique de mobilisation passive protégée selon Duran. L'attelle est du même type que celle utilisée pour la technique de Kleinert. L'articulation IPD est mobilisée passivement pour mobiliser le tendon fléchisseur profond par rapport au superficiel. La mobilisation passive de l'IPP permet de déplacer les fléchisseurs profond et superficiel par rapport à leur environnement tissulaire.



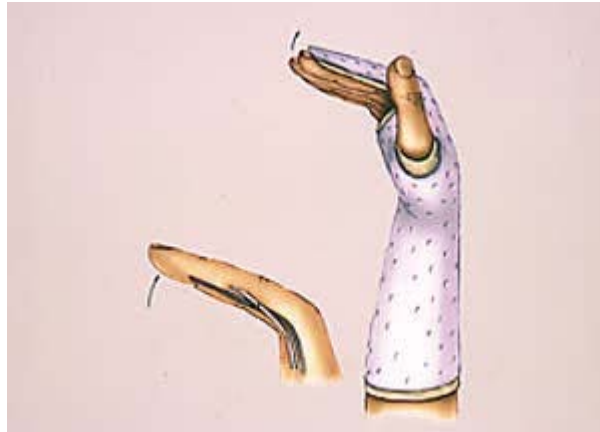


Fig. 12 bis

It is based on the principle of mobilization of the suture for 3-5 mm in the digit channel by making an active extension of the digit chain, entrusting the flex return to an elastic band secured to the nail and the tubercle of the scaphoid. A pulley system located opposite the distal palmar fold of the hand helps flex the PD and, thus, mobilize the superficial and deep flexors upon extension of the finger. The wrist being fixed at 30° of flexure, and the MPs at 60°, during the active extension of the finger, the flexor muscle is not placed under tension and does not trigger a "stretch reflex", which would threaten the suture.

Many failures have been reported with the Kleinert method. These are due to a mistake in the realization of the orthosis and the fixation of the elastic return band, but also to a lack of understanding on the part of the patient. In the latter case, we have our patient perform physical therapy everyday in order to achieve a passive mobilization per Duran, using the same splint for protection as that in the Kleinert method. The PD and IPP articulations are passively mobilized, which allows a mobilization of the superficial and deep tendons with respect to each other, and also with respect to the skeleton.

The most serious criticism which can be made of these two methods is their weak mobilization of the suture zones (3-5 mm), which is not enough to reduce adhesions and restore the sliding surface.

- Strickland et al. [21] have taken the option of an active protected reeducation of the flexors by enlarging their path thanks to the tenodesis effect of the wrist. This method involves making a dorsal orthosis articulated at the wrist. At rest, this is at 20° of flexure and the MPs are at W1, while the PPs are in total extension. The wrist is at first fixed by splint at 30° of dorsi-flexion, the fingers are passively flexed, MP at 60°, IPP and PD are coiled by virtue of the edema. The patient is then requested to maintain this position for a period of 5 seconds with the least possible muscle contraction. The patient then slackens the contraction, relaxes the wrist in flexure and the PPs in extension. This manoeuvre is repeated 25 times an hour for 4 weeks, after which the orthosis is released and active movements are progressively permitted, and then carried out freely in week 8, in order to prevent elongation of the tendon scar.

- The advantage of this method, which is easily understood by the patient and his or her physical therapist, is to significantly improve the functional result, and to avoid

the deficit of extension of the interphalangeal articulations, which is frequently found in the Kleinert method.

The reeducation protocol of the Indiana school (Strickland - Cannon - Gentle) [3-191], poorly understood, may result in rupture of the tendon repair or at least a significant elongation of the scar callus.

#### **- Complications and their treatment.**

- Locking of the tendon repair by adhesions, elongation of the callus or its rupture are still frequently encountered in event of trauma from crushing or avulsion of the tendon.

If the wound was free, a functional failure should cast doubt on the quality of the surgeon's repair and the protection by splint. The physical therapist should also be questioned as to the technical choice of the protected mobilization, active or passive, and the patient on his or her comprehension and diligence in performing the reeducation.

- Tenolysis should be contemplated 3-4 months after a primary repair and 6 months in the case of freeing up a graft from its adhesions.

It is a difficult operation to perform, since one should strive to preserve to the maximum the reflexion pulleys making up the digit channel (A1, A2, A3, A4), as well as at least half of the superficial flexor tendon. The tenolysis should systematically extend to the initial operative field and, if possible, be done in the digit area by an initially lateral approach.

The effectiveness of the tenolysis may be evaluated either by the active contraction of the flexors during the operation, if the patient has undergone a trunk blockade in the area of the wrist, or by the surgeon who tests the flexor tendon by a counterincision made at the proximal palmar fold of the wrist.

Systematically, we coat the entire tenolyzed tendon with the gel ADCON-GEL, in order to induce a glide surface and limit the initial fibroblastic colonization which leads to the formation of adhesions (Fig. 13.1 to 13.6).

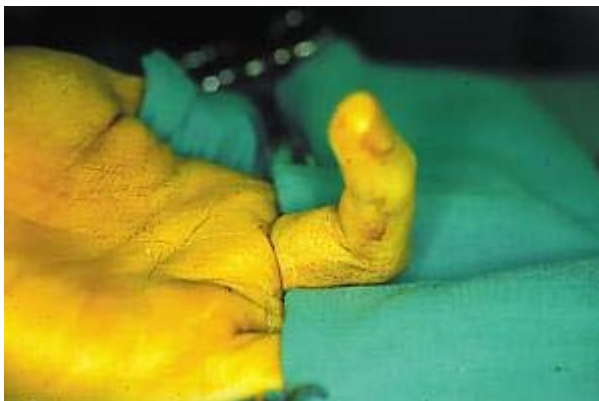

Fig. 13.1 Blocage tendineux en zone 2 et raideur de l'IPP.

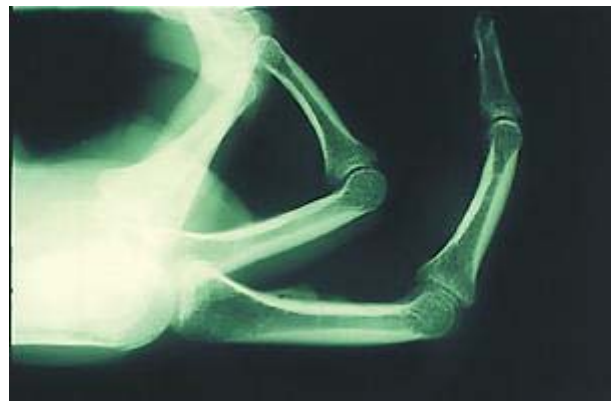

Fig. 13.2

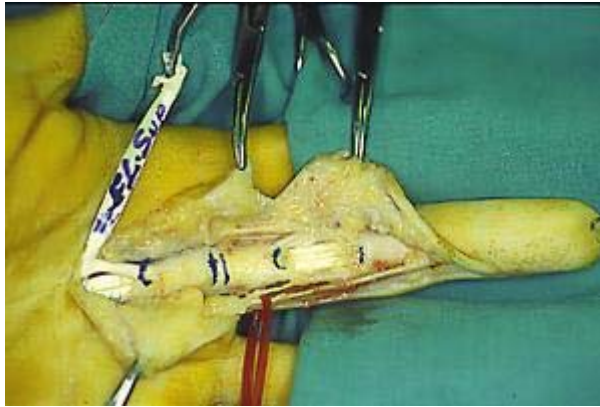


Fig. 13.3 Ténolyse des fléchisseurs superficiel et profond qui sont enduits d'ADCON-GEL-GEL-T/N

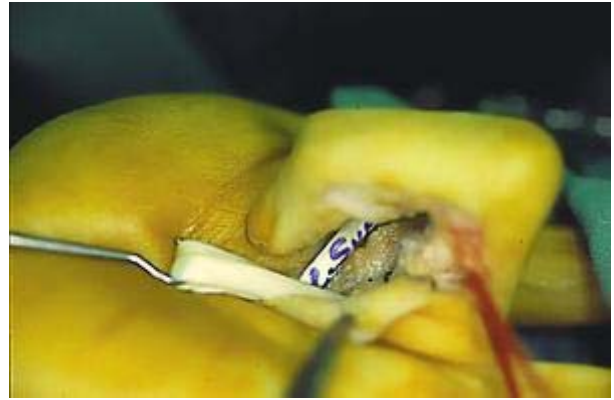

Fig. 13.4 à l'issue de l'intervention.

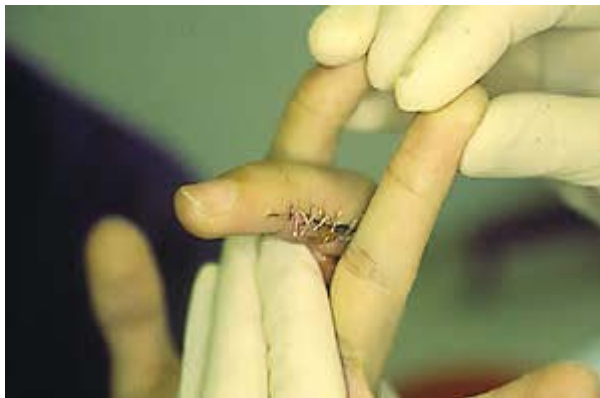

Fig. 13.5 Rééducation précoce active.

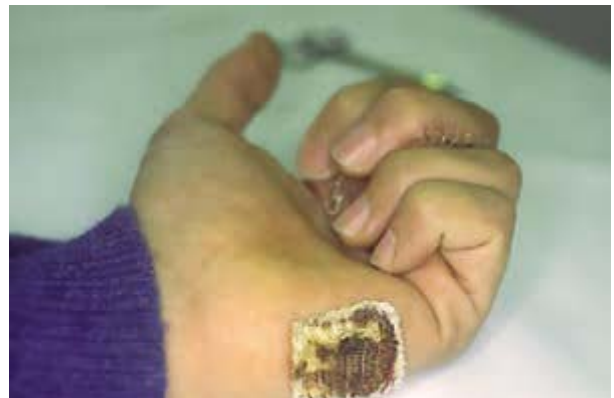

Fig. 13.6 Résultat à 8 jours.

- Elongation of the callus is only identifiable when it results in rupture. Surgical resumption should be quick, since there is no sense in allowing the muscle-tendon retraction to become established. If the rupture appears in the days following the primary repair, one is warranted in attempting a second suture, unless the tendon was originally contused or avulsed.

- Tendon graft in a single procedure is justified when the system of pulleys is preserved and the tissue bed is of good quality. It is common in such cases to make short grafts, the proximal suture being done by lacing up in the palm of the hand (Pulvertaft) and the fixation to the distal phalanx by an anchor or by a pullout type procedure.

- A graft requiring two procedures is reserved for repair of a deep flexor when the superficial tendon is intact, or when local conditions require the reconstruction of pulleys and the induction of a new glide sheath by means of a silicone rod left in place for 8 weeks.

The grafts are most often long and anastomose to the wrist.

All these graft techniques are compatible with the active or passive protected mobilization techniques described above.

## **B) The extensor tendons.**

- The surgical technique here is less constrained, but it should still be precise for fixing tendon ruptures in zone 1 (Finger Mallet) or in zone 3 (Buttonhole).

The barbwire of Jennings, long used in France (Allieu) [2], has given way to the Mitek mini-anchor (Fig. 14).

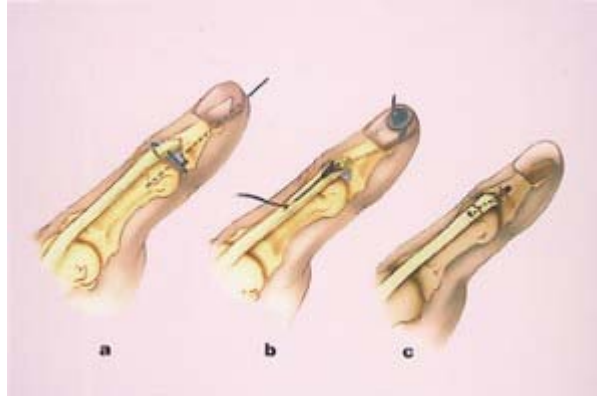


Fig. 14 a) Réinsertion du tendon terminal et de son fragment osseux par un cerclage métallique au fil PDS 2 ou 3/0. Une broche de Kirschner fixe l'articulation en extension pour 4 semaines.

b) Réinsertion par le Barb-Wire de Jennings. L'ardillon vient de plaquer le fragment osseux sans être transfixié par le fil métallique. Celui-ci chemine ensuite à travers la phalange distale, contourne la houe et vient se bloquer sur l'angle à l'aide du plomb.

c) Réinsertion du tendon extenseur à l'aide d'un micro ou mini-ancreur Mitek.

In zone 5-6-7, the tendons are less bulky and will tolerate sutures of Kleinert, Tsuge, Tajima-Kessler type.

- Post-operative protected mobilization entails the emplacement of a low-profile or thesis, one which allows an active IVIP-1P flexure between 0 and 600 during the first 34 weeks after the operation, the automatic return in extension occurring by elastic bands. The wrist is fixed at 30° in dorsi-flexion to avoid the "stretch reflex" of the extensor muscles of the fingers.

- Elongation of the tendon callus is also common and reduces the functional result, especially for lesions in zone 1 and 3. Rupture of the suture is less common than in surgery of the flexors, but if it occurs in zone 5-6-7 the repair can be left to a graft, in one or two procedures, depending on the tissue environment. For patients not having an absolute need to recover independence of the fingers, the common extensor that is ruptured can be fixed to the adjacent healthy extensor (preferred indication in rheumatoid polyarthritis).

- Adhesions remain the major complication of surgery on the extensor tendons. Paradoxically, they are manifested by a deficit in flexion of the fingers, while the extension is most often intact because of the tenodesis effects of the wrist.

In crush trauma of the digit chains, adhesions to the metacarpals, the first phalanx and the cutaneous integument are common. The tenolysis should frequently be extended.

- The post-operative reeducation is also important during the first 8 days, but also in the 3rd week, when we have often observed an upsurge in the fibroblastic reaction.

### **C) Surgery of tendon transfers.**

- This is a functional salvage surgery, often very effective in treating paralytic sequela. It involves multiple access points, substantial detachments, and many sutures between tendons.

We have sought to minimize the risks of adhesions by multiplying the small cutaneous incisions to facilitate the passage of tendon transfers, which minimizes the detachments.

Yet after 3 or 4 weeks of splint immobilization, we have been surprised by the scant mobility of the tendon transfer, which functions more by the tenodesis effect of the wrist than by natural excursion. In order to test the action of the gel ADCON-GEL at minimizing adhesions and improving the sliding action of the tendon transfers, we carried out a double blind study.

A metal index included in the area of the anastomoses between tendons makes it possible to evaluate the course of the tendon transfers in terms of millimeters [161].

### **D) How to avoid adhesions and induce a sliding surface.**

- Many attempts have been made to resolve this problem with recourse to cellulose tubes, plates of Silastic, polyethylene, bovine pericardium, Gore-Tex, and Vicryl-collagen [101].

Other drug therapies have been proposed with varying success: corticoids, Ibuprofen, Indomethacin.

The advent of ADCON-GEL, which is a combination of a gelatine and a polyglycan ester, is a major contribution to tendon surgery, as revealed by many experimental and clinical works which we shall mention here.

## **1) Experimental testing.**

a) Tenolysis of the flexors of the rabbit paw.

- After partial sectioning of the flexor tendon, it is repaired and immobilized by plaster splint for 4 weeks (12 cases). A tenolysis is done 4 weeks later on, half of the series being treated with ADCON-GEL, the other half being the control. The paw is then immobilized with plaster for 6 weeks. Histological and biomechanical study revealed it was necessary to apply a force 6 times greater in the control group

than in the ADCON-GEL group to free the tendon from its adhesions. The force applied to free the tendon treated with ADCON-GEL was equivalent to that needed to mobilize a normal nonoperated tendon.

This study by Ahmad et al. [11] has shown that ADCON-GEL has a real inhibitory effect on peri-tendinous adhesions and does not produce any change in the tendon scarring or the surrounding tissues.

Our study [12] carried out on the common flexor of the fingers of rabbits (30 cases), according to a similar protocol, has revealed that the excursion of the tendons of the control group was 60% less than that of the group treated with ADCON-GEL.

#### b) Neurolysis of the sciatic nerve of the rat.

- Palatinsky et al. [17] have shown, after two surgical operations on the sciatic nerve of the rat (38 cases), that adhesions were less substantial in the group treated with ADCON-GEL during the second neurolysis and that no intraneural paraneural reaction had been induced.

Petersen et al. [19] have developed a protocol involving 3 types of graduated nerve lesions (neurolysis - abrasion - suture section).

They conclude that the group treated with ADCON-GEL has fewer perineural adhesions than the control group, and they observed no modification in the physiological characteristics of the nerve or its capacity for regeneration.

#### c) The influence of ADCON-GEL on vascular-nervous and tendinous elements.

- LAN et al. [7] have proven that ADCON-GEL had no influence on the vascular permeability after microsuturing of the femoral vessels of the rat, and that 5 weeks later redissection of these vessels was facilitated in the group treated with ADCON-GEL. These experimental animal studies reveal the anti-adhesion action of ADCON-GEL and its safety for repaired vascular-nervous elements. All of the surgeons were surprised by the ease of making a secondary resectioning of these elements, which led us to use this gel as early as the primary surgery.

## **2) Clinical studies.**

#### a) Tenolysis of the flexors and extensors.

- It has been more difficult to create clinical protocols, since homogenous groups of patients are hard to form. The surgeons at the Clinique Longeraie of Lausanne [16], who have applied ADCON-GEL in 15 patients compared the functional results to a control group of 17 patients.

The results showed the perfect tolerance and safety of ADCON-GEL, which induced neither infection nor allergy nor tendon rupture when the dose used was just enough to coat the tendon.

The functional benefit was in favor of the group treated with ADCON-GEL, since the gain in post-operative mobility was on average 36.7%, compared to 16.8% for the control group.

b) Open study of the SOS Main Strasbourg [16].

- Of 36 hands operated upon, 14 involved the flexor and extensor tendons, the other 13 were tendon transfers, tendon grafts and nerve repairs.

The author of this series confirms the good toleration of ADCON-GEL, absence of infection and tendon rupture. Its application is able to slow down the post-operative mobilization while still getting useful results. A single case in which the mobilization was #12 delayed to the 5th day after the operation developed adhesions.

The results were even more demonstrative for tenolysis of the extensor apparatus, since all the cases had functional improvement, and no complication of infection or rupture type was observed.

c) Surgery of tendon transfers [16].

- our experience with ADCON-GEL in tendon surgery is promising.

Our tendon transfer protocol used to treat the paralysis sequelae of median, radial and cubital nerves incorporates metal indices in the area of the anastomosis zones (21 cases). The purpose of ADCON-GEL in this particular indication is to prevent fibroblastic reactions and the numerous adhesions which appear both between the tendons and the subcutaneous tissues, and to the periosteum, which accounts for the major possibility of sliding action of the transfers.

The application of ADCON-GEL to all of the tendon transfers should reduce the risk of adhesions and improve the functional result. This double-blind study is still under way and will allow us to quantify the results by measuring, at the same time, the global mobility of the hand and of the wrist, and the excursion of the tendons transferred at 6 and 26 weeks after the operation. As for the safety of use of ADCON-GEL, we observed no undesirable effects.

## Conclusion

Surgery of the tendons of the hand and fingers is demanding in technical and reeducation respects. It requires perfect knowledge of anatomy, biomechanics, and the physiology of the scarring.

The proliferation of fibroblasts and collagen is an inevitable phase in tendon cicatrization. The action of the biodegradable gel ADCON-GEL has been demonstrated experimentally and clinically to suppress this phenomenon, while preserving the quality of cicatrization of the tendon and the other vascular-nervous structures.

A scrupulous technical realization, prolonged by a rigorous reduction combined with the use of the biodegradable gel ADCON-GEL, enables a significant improvement in the functional outcome of the tendon surgery, long held to be haphazard.

*Les figures sont extraites de :*  
*La Main traumatique : l'urgence 2ème édition avec CD-ROM*  
*M. MERLE - G. DAUTEL - MASSON PARIS 1997*

## **RÉFÉRENCES**

- 1) AHMAD S., HINGSON M., MAIER K., TOUHALISKY D., COCKER G.  
Inhibition of peritendinous adhesions by ADCON-GEL in tenolysis, 2nd Congress of the Federation of European Societies for Surgery of the Hand, Dublin, Ireland, June 1994.
  
- 2) ALLIEU Y., ROMIEU.  
L'utilisation du Barb-Wire de Jennings dans les sutures tendineuses. Absence d'immobilisation post-opératoire.  
Ann. Chir., 1971, 25, 987-994.
  
- 3) CANNON N.M.  
Post flexor tendon repair motion protocol.  
The Indiana Hand Center Newsletter 1993 - 1 : 13-17.
  
- 4) DURAN R.J., HAUSER R.G.  
Controlled passive motion following flexor tendon repair in zones two and three.  
AAOS Symposium on tendon surgery in the hand, 9, 182-189. C.V. Mosby, Saint-Louis, 1975.
  
- 5) KESSLER I.  
The "grasping" technique for tendon repair.  
The Hand, 1973, 5, 253-255.
  
- 6) KLEINERT H.E., KUTZ J.E., ASHBELL T.S., MARTINEZ E.  
Primary repair of lacerated flexor tendon in "no man's land".  
J. Bone Joint Surg., 1967, 49 A, 577.
  
- 7) LAN G., De MEDINACELI L., MERLE M..  
Experimental effects of ADCON-GEL on the healing of blood vessels, Submitted for presentation at the 65th Annual meeting of the American Association of Neurological Surgeons, Denver, April, 1997.
  
- 8) LINDSAY W.K. and THOMDON H.G.  
Digital flexor tendons : An experimental study, Part I. The significance of each component of the flexor mechanism in tendon healing.  
British Journal of Plastic Surgery 1960, 12, 289-319.



- 9) LISTER G.D.  
Reconstruction of pulleys employing extensor retinaculum.  
J. Hand Surg., 1979, 4, 461-464.
- 10) MAINARD D., GUTH P.C., LEROUX P., MERLE M., MICHON J.  
Comparaison expérimentale et clinique de trois biomatériaux pour la restauration du glissement tendineux en chirurgie de la main. Benichoux R., Lacoste J., eds. Progrès récents des biomatériaux.  
Paris : Masson, 1988, 193-210.
- 11) MANSKE P.R.  
Flexor tendon Healing.  
J. Hand Surg., 1988, 13 B, 237-245.
- 12) MERLE M., DAUTEL G., De MEDINACELI L.  
Inhibition of peritendinous adhesions by ADCON-GEL in a rabbit flexor tendon model, 6th Congress of the International Federation of Societies for Surgery of the Hand, July, 1995.
- 13) MERLE M., DAUTEL G.  
La Main Traumatique : 1 l'urgence.  
Masson éditeur PARIS, 2ème édition 1997.
- 14) MERLE M., FOUCHER G., MICHON J.  
La technique de Kleinert pour la réparation primaire des tendons fléchisseurs dans le "no man's land".  
Ann. Chir., 1976, 11-12, 883-887.
- 15) MERLE M., FOUCHER G., MICHON J.  
Extraction atraumatique du bout proximal du tendon fléchisseur.  
Ann. Chir., 1977, 31, 357.
- 16) MERLE M., FOUCHER G., EGLOFF D.V.  
Peritendinous and perineural scar and adhesions. Treatment with a new anti adhesion barrier gel, ADCON-GEL.  
In Hand Surgery REHART S., ZICHNER L. Thieme Stuttgart 1997, 33-40.
- 17) PALATINSKY E.A, MAIER K.H, TOUHALISKY D.K, MOCK J.K,  
HINGSON M.T, COCKER G.T.  
ADCON-GEL reduces in vivo perineural adhesions in a rat sciatic nerve neoperation model.  
J. Hand Surgery 22 B, 1197, (3), 331-335
- 18) PEACOCK E.E.  
Biological principles in the healing of long tendons.  
Surgical clinics of North-America, 1965, 45, 2, 461-476.

19) PETERSEN J., RUSSEL L., ANDRUS K., MAC KINNON M., SILVER J., KLIOT M.

Reduction of extraneural scarring by ADCON-GEL after surgical intervention.  
Neurosurg., 1996, 38, 976-83.

20) POTENZA A.D.

Tendon healing within the flexor digital sheath in the dog.  
Journal of Bone and Joint Surgery 1962, 44 A, 49-64.

21) STRICKLAND J.W.

Flexor tendon injuries in the Hand. Master technique in orthopaedic surgery.  
J.W. STRICKLAND Lippincott - Raven Philadelphia 1998, 473-489.

22) TSUGE K., IKUTA Y., MATSUSHI Y.

Intratendinous tendon suture in the hand. A new technique.  
The Hand, 1975, 7, 250-255.

23) VERDAN C.

Primary and secondary repair of flexor and extensor injuries.  
In : FLYNN J.E., Hand Surgery. Williams and Wilkins, Baltimore, 1966.

24) WEBER E.R.

Synovial fluid nutrition of flexor tendons.  
Orthop. Res. Soc., 1979, 4, 227.